

Case Report

## Immunoserologically Diagnosed Toxocariasis with Bilateral Pleural Effusion

HARUHIKO MARUYAMA<sup>1</sup>), TAKAHIKO KOBAYASHI<sup>1</sup>), MASAKI TOMITA<sup>1</sup>), HIROSHI ITOH<sup>1</sup>), YOSHIHIDE HIRAMOTO<sup>2</sup>), YUTAKA ENDO<sup>2</sup>), SHINGO TAKADA<sup>2</sup>), HIROKI KOSAKAMOTO<sup>2</sup>), KEIKO IMAKADO<sup>2</sup>), TETSUSHI YOSHIMATA<sup>2</sup>), IKUO NAKAMURA<sup>2</sup>) AND YUKIFUMI NAWA<sup>1</sup>)

<sup>1</sup>)Department of Parasitology, Miyazaki Medical College, Kiyotake, Miyazaki 889-16, Japan.

<sup>2</sup>)Department of Internal Medicine, Miyazaki Seikyo Hospital, Wachigawara, Miyazaki 880, Japan.

(Accepted June 1, 1995)

**Key words:** toxocariasis; *Toxocara canis*; lung; pleural effusion; liver; eosinophilia.

Toxocariasis is a representative zoonotic parasitosis in developed countries (Glickman and Schantz, 1981), which is characterized as visceral larva migrans (VLM: Beaver *et al.*, 1952), and is primarily a disease of children. Apart from ocular involvement, typical form of VLM caused by *Toxocara* infection is a pulmonary infiltration with eosinophilia (PIE) syndrome frequently associated with liver function disorders, although most of clinical symptoms associated with toxocariasis is rather nonspecific. In this report we describe a rare form of toxocariasis occurred in an old woman, who showed bilateral eosinophilic pleural effusion. Efficacy and limitations of immunoserological diagnosis is discussed.

### Case Report

The patient is an 85 yr-old woman born and grown up in Miyazaki Prefecture, Japan. She has never been abroad. She had eaten undercooked beef meat ("Tataki") about two months before the onset of the illness. She has never eaten freshwater crab or uncooked chicken, wild boar or other animal meats. She has never kept pet dogs or cats, though she sometimes plays with a dog of her neighbor. In the

early July 1994, general fatigue developed but liver functions were within normal range. She sustained general fatigue and high fever developed in the early August, so that she was admitted to a regional hospital on August 13. On admission, a plain chest radiogram (Fig. 1) and computed tomogram (CT: Fig. 2) showed bilateral pulmonary infiltrations with massive pleural effusion. Her laboratory data were as follows; total white blood cell count: 6,700/mm<sup>3</sup> with 8% eosinophils, red blood cell count: 422×10<sup>4</sup>/mm<sup>3</sup>, hemoglobin level: 11.0 g/l. Liver enzyme levels elevated (GOT 105 IU/l, GPT 77 IU/l, LDH 1,441 IU/l). She had been treated with antibiotics (CEZ 2 g/day), which was ineffective. Her laboratory data had been getting worse; on August 24, white blood cell count: 9,200/mm<sup>3</sup> with 8% eosinophils, GOT: 118 IU/l, GPT: 112 IU/l, LDH: 2,005 IU/l. Pleural effusion obtained on August 24 was slightly turbid, pale yellow in color, and contained 3.4 g protein/dl. Its specific gravity was 1.026. Cytologically the pleural effusion contained 10,250 cells/mm<sup>3</sup>, of 57% were eosinophils. Neither malignant cells nor bacteria were found in the pleural effusion. Tumor markers including carcinoembryonic antigen, neuron-specific enolase, sialyl Le<sup>x</sup> were negative. At this stage, parasitic disease was strongly suspected so that the samples of her serum and pleural effusion obtained on August 30 were sent to the Department of Parasitology, Miyazaki Medical College. Her serum and the pleural effusion gave positive reaction against *T. canis*

Correspondence: Yukifumi Nawa

丸山治彦<sup>1</sup>, 小林隆彦<sup>1</sup>, 富田雅樹<sup>1</sup>, 伊藤浩史<sup>1</sup>, 名和行文<sup>1</sup>, 平元良英<sup>2</sup>, 遠藤 豊<sup>2</sup>, 高田慎吾<sup>2</sup>, 小坂本博揮<sup>2</sup>, 今門敬子<sup>2</sup>, 吉俣哲志<sup>2</sup>, 中村育夫<sup>2</sup> (<sup>1</sup>宮崎医科大学寄生虫学講座, <sup>2</sup>宮崎生協病院)

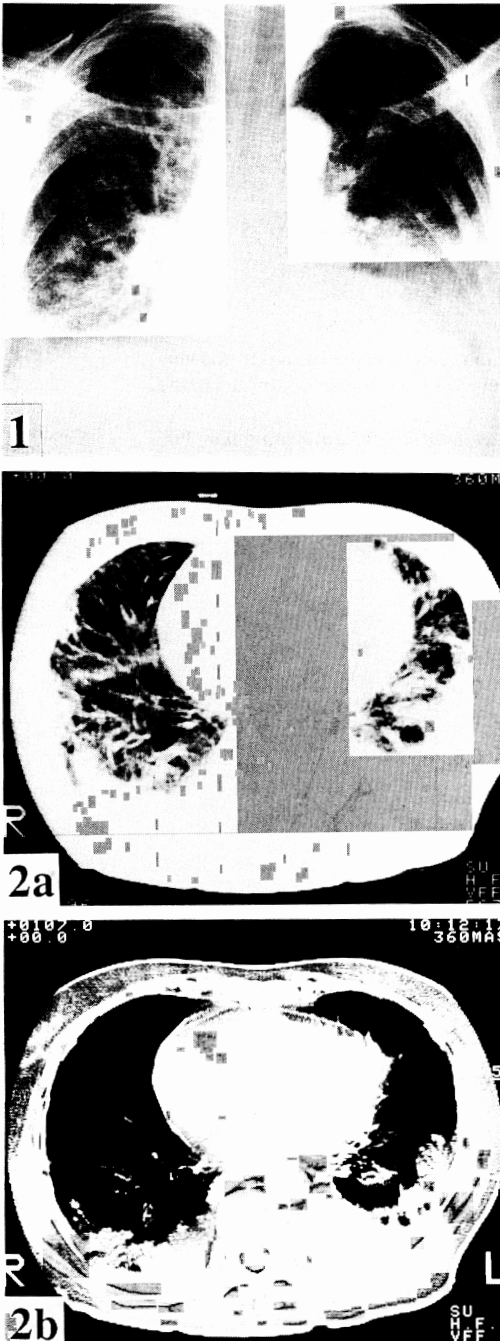


Fig. 1 Plain chest radiogram showing bilateral infiltration and bilateral pleural effusion.

Fig. 2 Computed tomogram of the patient. Note bilateral multiple infiltrations (a) and pleural effusion (b).

antigen and also against some other nematode antigens with lesser intensity by a multiple-dot ELISA test for parasitic diseases (Fig. 3). Specific binding of the patient's serum to *T. canis* antigen was confirmed further by inhibition ELISA. Wells of microtiter plates were coated with crude extract from the mixture of *T. canis* adult male and female worms and the inhibition by various parasite antigens on the binding of the patient serum to the *T. canis* antigen was measured by ELISA. *T. canis* antigen completely inhibited the binding of the patient serum to the antigen, but other antigens did not (Fig. 4). *T. canis* antigen caused 50% inhibition of the binding at about 3  $\mu\text{g}/\text{ml}$ , whereas more than 100  $\mu\text{g}/\text{ml}$  was required to obtain 50% inhibition by antigens of *Ascaris lumbricoides suum*, *Anisakis simplex*, or *Gnathostoma doloresi*. Antigens of other parasites or bovine serum albumin did not inhibit the binding. To identify the causative species of the disease, binding specificity of the serum to antigens of three ascarid species, *T. canis*, *T. cati* and *A. lumbricoides suum*, was measured by ELISA. Binding of the patient's serum to *T. canis* antigen was consistently higher than that to *T. cati* or *A. lumbricoides suum* antigens (Fig. 5). Binding of the patient's serum to *T. canis* antigen was inhibited equally by *T. canis* and *T. cati* antigens (Fig. 6a). Similar result was obtained when *T. cati* antigen was used as the target (Fig. 6b). From these data, the patient was diagnosed immunoserologically with toxocariasis canis. The patient received two sets of oral administration of mebendazole (200 mg/day) for 3 days from September 14 and 21. Clinical course of the patient is summarized in Fig. 7. Specific antibody titers, leukocytosis, and eosinophilia gradually decreased with time. One month after the treatment, chest radiographic findings and liver functions were markedly improved except for continuous elevation of  $\gamma$ -globulin.

## Discussion

Eosinophilic pleural effusion is observed in a wide variety of diseases, especially pneumothorax after trauma (Darbyshire and Chandler, 1984), infections including tuberculosis (Mihailescu and Micu, 1985), and more rarely in patients with malignant diseases, asbestosis, pulmonary infarction, and

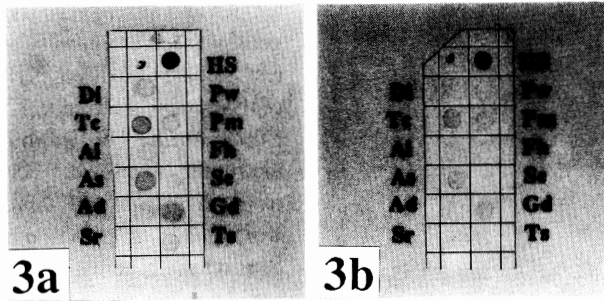


Fig. 3 Multiple-dot ELISA of the patient serum (a) and pleural effusion (b) showing positive reaction against *T. canis* antigen with cross reactions against other parasite antigens.

Di: *Dirofilaria immitis*, Pw: *Paragonimus westermani*, Tc: *Toxocara canis*, Pm: *Paragonimus miyazakii*, Al: *Ascaris lumbricoides*, Fh: *Fasciola hepatica*, As: *Anisakis simplex*, Se: *Spirometra erinacei*, Ad: *Ancylostoma duodenale*, Gd: *Gnathostoma doloresi*, Sr: *Strongyloides ratti*, Ts: *Trichinella spiralis*

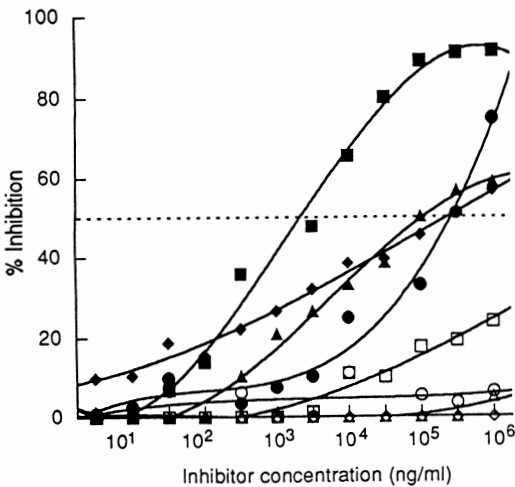


Fig. 4 Inhibition of the binding of the patient's serum by various parasite antigens. Aliquots of the patient's serum (diluted 1:100) were incubated with various concentrations of a panel of parasite antigens at 4°C overnight, and then the binding to *T. canis* antigen was measured in ELISA.

(■) *T. canis*, (●) *A. lumbricoides*, (▲) *A. simplex*, (◆) *G. doloresi*, (□) *D. immitis*, (○) *A. duodenale*, (△) *S. ratti*, (◇) *P. westermani*

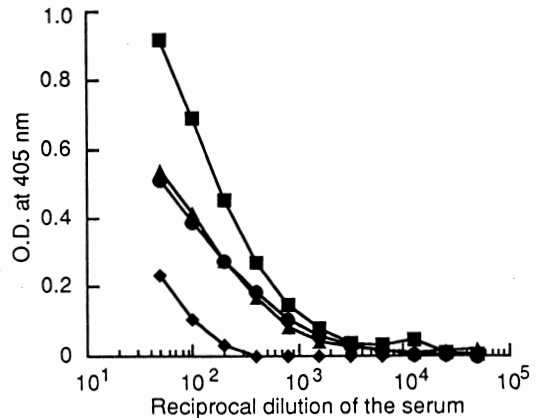


Fig. 5 Binding of the patient's serum to three *Ascarididae* antigens.

Wells of microtiter plates were coated with 10 µg/ml each of *T. canis* (■), *T. cati* (●) and *A. lumbricoides suum* (▲) antigens, and bovine serum albumin (◆). The patient's serum of various concentrations were added to the wells and the binding was measured in ELISA.

autoimmune diseases (Spry, 1988). Among infectious diseases, eosinophilic pleural effusion is most frequently associated with paragonimiasis, because

pleural cavity is in a migration route of the parasite. The patient reported here was initially suspected with paragonimiasis because Miyazaki Prefecture is an endemic area of paragonimiasis (Nawa, 1991). However, a multiple dot-ELISA test showed that the patient's serum and pleural effusion contained spe-

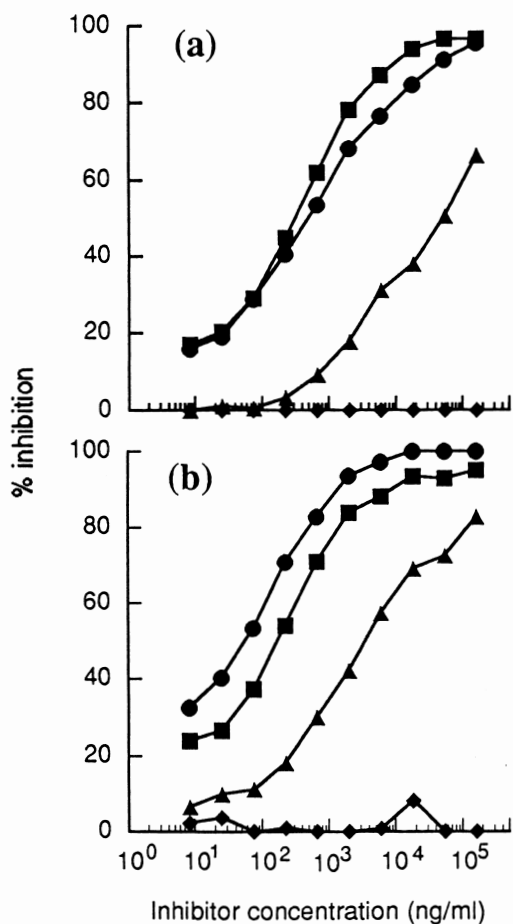


Fig. 6 Inhibition of the binding of the patient's serum by three *Ascarididae* antigens.

Various concentrations of *T. canis* (■), *T. cati* (●) and *A. lumbricoides* (▲) antigens were incubated with the equal volume of the patient's serum (diluted 1:100) at 4°C overnight. The mixture was added to the ELISA plate coated with 10 µg/ml of *T. canis* (a) and *T. cati* (b) antigens. The binding was measured in ELISA and the % inhibition was calculated relative to buffer control.

cific antibodies to *T. canis* antigen but not to *P. westermani* or *P. miyazakii* antigens. Specificity of the binding of the antibodies was confirmed further by a microplate ELISA. These results indicate an advantage of a multiple-dot ELISA test for a rapid screening of parasitic diseases. Application of dot-ELISA for toxocariasis has already been reported

(Camargo *et al.*, 1992).

In the present study, reliability of the diagnosis was examined further by a binding assay and ELISA-inhibition tests. Binding of the patient's serum to *T. canis* antigen was almost completely inhibited by the homologous antigen and far lesser extent by three other nematode antigens, *A. lumbricoides*, *A. simplex* and *G. doloresi*, but was not inhibited by other parasite antigens. Binding of the patient's serum to *T. canis* antigen was higher than the other two *Ascarididae* antigens, *T. cati* and *A. lumbricoides*. In the inhibition tests using three *Ascarididae* antigens, however, the binding of the patient's serum to *T. canis* antigen was almost equally inhibited by *T. canis* and *T. cati* antigens and far lesser extent by *A. lumbricoides suum* antigen. Similarly, the binding to *T. cati* antigen was also equally inhibited by *T. cati* and *T. canis* antigens. Therefore, based on the binding assays, the patient was diagnosed with toxocariasis, presumably be toxocariasis canis, though the inhibition tests could not discriminate two species of *Toxocara*, *T. canis* and *T. cati*. In the present study, we used crude whole worm extracts as antigens. Since Nagakura *et al.* (1990) reported that *T. canis* and *T. cati* could be discriminated from each other by immunoserological methods using excretory-secretory (ES) antigens, ES antigens of various parasites should be, if available, included in our assay system.

Because of the route of migration of *T. canis* larvae, liver and lungs are the commonest site affected in human toxocariasis (Oshima, 1990). In this regard, the patient reported here showed typical clinical manifestations such as eosinophilia, liver function disorders, and pleuro-pulmonary lesions, though these signs and symptoms were not unique to toxocariasis. Granulomatous lesions in the liver of toxocariasis patients were frequently observed as multiple hypoechoic areas by ultrasonography (Clarke *et al.*, 1992; Ishibashi *et al.*, 1992; Bhatia and Sarin, 1994). Pulmonary involvement in toxocariasis is characterized as Löffler syndrome (Oshima, 1990; Roig *et al.*, 1992). The patient reported here showed bilateral diffuse pulmonary infiltration and pleural effusion, indicating the severity of the infection. After immunoserological diagnosis, the patient was treated effectively with mebendazol. Efficacy of benzimidazole derivatives

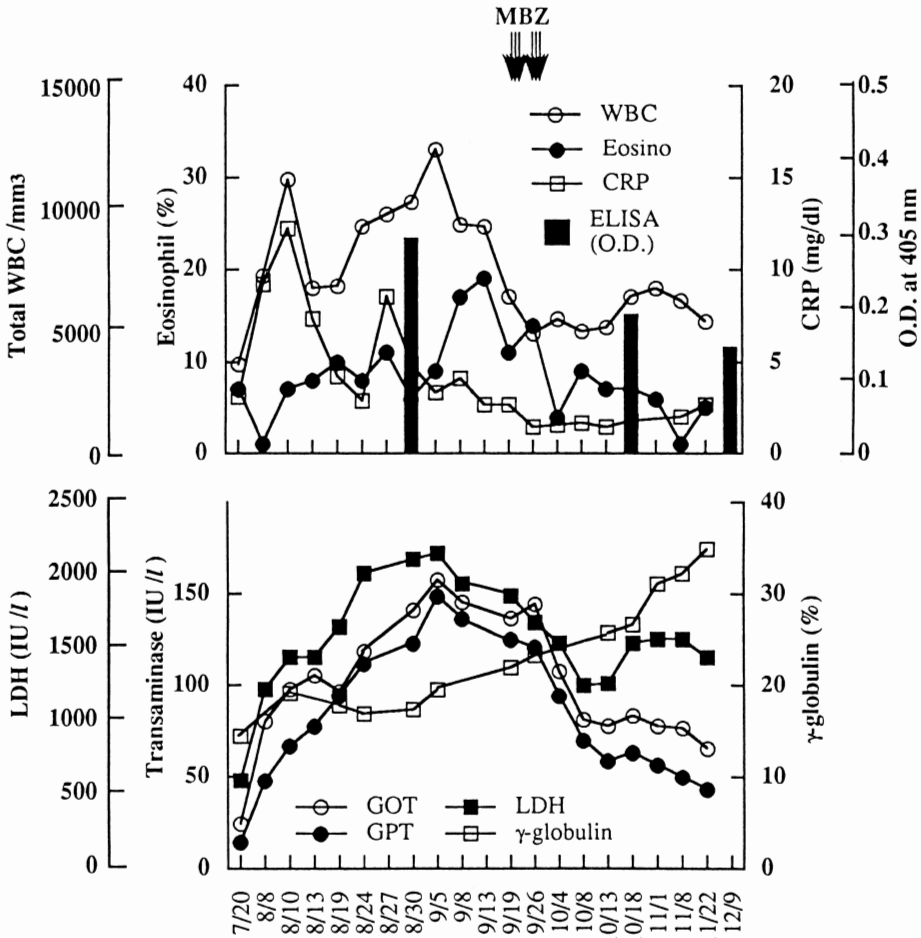


Fig. 7 Clinical course of the patient. Total white blood cell count (WBC), % of eosinophils, C-reactive protein (CRP), and the specific antibody titers measured by ELISA (closed column) are shown in the upper panel. The parameters related to liver functions are shown in the lower panel.

for the treatment of toxocariasis has been well established (Oshima, 1990; Krcmery *et al.*, 1992; Bhatia and Sarin, 1994). Since disseminated toxocariasis is occasionally found in immuno-compromised hosts, careful follow-up study is necessary to rule out any underlying diseases in the present patient.

In conclusion, immunoserological diagnosis using multiple-dot ELISA, and the binding and inhibition assays using microplate ELISA are useful for rapid and reliable diagnosis of toxocariasis, though

these methods still have limitations of the identification of the exact causative pathogen.

**Acknowledgements**

The authors wish to thank Dr. T. Oshima, Prof. Emeritus of Yokohama City University, School of Medicine, and Dr. K. Araki, Department of Immunology and Parasitology, the National Institute of Public Health, for their valuable advice and discussion. Excellent technical assistance of Ms. A. Tanaka is gratefully acknowledged.

## References

- 1) Beaver, P. C., Snyder, C. H., Carrera, G. M., Dent, J. H. and Lafferty, J. W. (1952): Chronic eosinophilia due to visceral larva migrans. Report of three cases. *Pediatrics*, 9, 7–19.
- 2) Bhatia, V. and Sarin, S. K. (1994): Hepatic visceral larva migrans: evolution of the lesion, diagnosis, and role of high-dose albendazole therapy. *Am. J. Gastroenterol.*, 89, 624–627.
- 3) Camargo, E. D., Nakamura, P. M., Vaz, A. J., Da-Silva, M. V., Chieffi, P. P. and De-Melo, E. O. (1992): Standardization of dot-ELISA for the serological diagnosis of toxocariasis and comparison of the assay with ELISA. *Rev. Inst. Med. Trop. Sao-Paulo*, 34, 55–60.
- 4) Clarke, H. M., Hinde, F. R. and Manns, R. A. (1992): Case report: hepatic ultrasound findings in a case of toxocariasis. *Clin. Radiol.*, 46, 135–136.
- 5) Darbyshire, P. G. and Chandler, G. N. (1984): Pleural fluid eosinophilia in association with trauma. *Br. J. Clin. Pract.*, 38, 326.
- 6) Glickman, L. T. and Schantz, P. M. (1981): Epidemiology and pathogenesis of zoonotic toxocariasis. *Epidemiol. Rev.*, 3, 230–250.
- 7) Ishibashi, H., Shimamura, R., Hirata, Y., Kudo, J. and Onizuka, H. (1992): Hepatic granuloma in toxocaral infection: role of ultrasonography in hypereosinophilia. *J. Clin. Ultrasound*, 20, 204–210.
- 8) Krcmery, V. Jr., Gould, I., Sobota, K. and Spanik, S. (1992): Two cases of disseminated toxocariasis in compromised hosts successfully treated with mebendazole. *Chemotherapy*, 38, 367–368.
- 9) Michailescu, E. and Micu, D. (1985): Eosinophilia in the pleural and peritoneal effusions. *Med. Interne*, 23, 191–194.
- 10) Nagakura, K., Kanno, S., Tachibana, H., Kaneda, Y., Ohkido, M., Kondo, K. and Inoue, H. (1990): Serologic differentiation between *Toxocara canis* and *Toxocara cati*. *J. Infect. Dis.*, 162, 1418–1419.
- 11) Nawa, Y. (1991): Recent trends of paragonimiasis *westermani* in Miyazaki Prefecture, Japan. *Southeast Asian J. Trop. Med. Public Health*, 22 (Suppl.), 342–344.
- 12) Oshima, T. (1990): *Toxocariasis canis* and *cati*. *Rinsyo-i (Clinician)*, 16, 318–322 (in Japanese).
- 13) Roig, J., Romeu, J., Riera, C., Texido, A., Domingo, C. and Morera, J. (1992): Acute eosinophilic pneumonia due to toxocariasis with bronchoalveolar lavage findings. *Chest*, 102, 294–296.
- 14) Spry, C. J. F. (1988): Respiratory tract diseases. In: *Eosinophils. A Comprehensive Review and Guide to the Scientific and Medical Literature*. Oxford University Press, Oxford, pp. 193–212.